

HISTOLOGICAL AND IMMUNOHISTOCHEMICAL ASPECTS OF CUTANEOUS LEISHMANIASIS IN NICARAGUA

Cesare MARISCOTTI (1), Mattia BARBARESCHI (1), Eduardo MISSONI (2), Rosella MORELLI (3), Uriel GUEVARA (4) & Juan MUNGUÍA-BARRERA (4)

SUMMARY

Sixty skin biopsies of fifty-eight non-treated patients with cutaneous leishmaniasis from Nicaragua were studied. Biopsies were classified according to Ridley's histopathologic groups: 36 (60%) were included in group B (diffuse necrosis), 14 in group C (focal necrosis), 7 (11.6%) in group D (reactive tuberculoïd). Only three biopsies remained unclassified.

None of our cases could be included in groups A and E.

Immunohistochemistry disclosed in 17 cases Russel's bodies secreting IgM and only one IgG positive. There was no correlation between the histopathologic groups and the presence of Russel's bodies. However, we believe the presence of Russel's bodies help the diagnosis of leishmaniasis. Correlation between morphological patterns and the different leishmania species was also considered.

KEY WORDS: Cutaneous leishmaniasis — Nicaragua; Pathology; Histological classification; Immunohistochemistry; Russel's bodies.

INTRODUCTION

New World cutaneous leishmaniasis is a disease characterized by various and complex histological pictures, in which the presence of amastigotes, as a diagnostic criterion, is not always evident^{3,8,9,13,16,17,20}. This is a fundamental difference with Old World Leishmaniasis, where parasites are generally numerous^{1,8,12,13,15,18,19,25}. The histological classification and diagnostic patterns have always been difficult to establish but the approach defined by RIDLEY & RIDLEY¹⁷ permits an aetiopathogenetic interpretation with possible clinical prognostic correlations^{14,15,16,17}. In this classification defense mechanisms are emphasized, assuming that their principal element is the immunologically determined necrosis of ma-

crophage-containing amastigotes^{6,13,16,17}. This classification, suggesting 5 types of tissue response (A, B, C, D, E), was particularly useful in the present study for evaluation of skin biopsies.

Recently MORIEARTY et al.¹¹ using the immunofluorescent test, identified in the dermal layers of cutaneous leishmaniasis lesions, high number of plasma cells, containing globular intracytoplasmic inclusions consisting of immunoglobulins (Russel bodies), mainly IgM and, to a minor degree, IgG. Likewise, in a previous investigation on skin biopsies of cutaneous leishmaniasis from Nicaragua³, we also found the presence of Russel bodies. They

(1) 3rd. Chair of Morbid Anatomy and Histopathology, University of Milan, Italy.

(2) Health Center "Fidel Ventura", Waslala, Republic of Nicaragua.

(3) Department of Infectious Diseases, City Hospital "L. Sacco", Milan, Italy.

(4) Department of Pathology, Leon University, Nicaragua.

Address for correspondence: Prof. Cesare Mariscotti. III Cattedra di Anatomia ed Istologia Patologica. Via Commenda 19; I — 20122 Milano, Italy.

were mostly immunoreactive for immunoglobulins M (IgM) and were of unclear diagnostic significance.

The purpose of the present work is: firstly, to define the histological patterns of Cutaneous Leishmaniasis in Nicaragua, where epidemiological and morphological aspects of the disease are still under investigation and, subsequently to evaluate if there is a relationship between a specific type of tissue reaction and the presence of Russel bodies in the infiltrate.

MATERIAL AND METHODS

Sixty biopsies from 58 Nicaraguan patients suffering from untreated cutaneous leishmaniasis were studied. Fifty patients came from the Health Centres of the VI Region (Matagalpa-Jinotega), corresponding to Northern and central areas of the country. The remaining 8 patients were observed in the Department of Pathology, Leon University, and came from different zones not geographically identified. Cases from the VI Region were diagnosed based on clinical, epidemiological and histological data: for 42 patients (72.4%) a skin test with leishmanin was performed with positive results.

Formalin-fixed and paraffin embedded sections were stained with haematoxylin-eosin, Giemsa, PAS, Ziehl-Neelsen and silver impregnation for reticulin fibres. Sections were stained immunohistochemically with peroxidase-antiperoxidase technique²¹ for the detection of IgG and IgM.

Lesion were classified according to RIDLEY & RIDLEY¹⁷ into the following histological groups: diffuse necrosis (type B); focalized necrosis (type C); reactive tuberculoid (type D). This classification, based on the presence of macrophages, granulomas, necrosis, lymphocytes, plasma cells and giant cells, is described in detail in ref. 17.

To evaluate the presence of parasites in the lesions, we used the parasite index (PI), according to RIDLEY & RIDLEY¹⁷.

This is a semilogarithmic index, ranging from 0 to 6. Each value corresponds to the number of amastigotes present in a given section, called "standard section" which is 4μ

thick, completely occupied by a lesion of cutaneous leishmaniasis, covering three microscopic fields when observed with a x 10 objective. The approximate correspondences between PI value and the number of amastigotes are as follows:

6 = 10 ⁵ or more amastigotes per standard section				
5 = 10 ⁴	"	"	"	"
4 = 10 ³	"	"	"	"
3 = 10 ²	"	"	"	"
2 = 10 ¹	"	"	"	"
1 = 1	"	"	"	"
0	no	"	"	"

The lowest scores were obviously easy to define, whereas the highest were uncountable.

RESULTS

The 60 skin biopsies were classified in four groups, as detailed in table 1, according to RIDLEY¹⁷. Thirty-six biopsies (60%) belonged to the "diffuse necrosis group" or "type-B group". These lesions are characterized by macrophage granulomas, fairly heavily infiltrated with lymphocytes and plasma cells. Dead macrophages, either isolated or in small clusters, can be detected and karyorrhexis may be marked (Fig. 1 and 2). As the lesions become more chronic, they are seen to have poorly demarcated clusters of immature epithelioid cells.

Fourteen cases (23.7%) belonged to the "focalized necrosis group" or "type - C group". The hallmark of these biopsies is a focalized macrophage granuloma, surrounded by lymphocytes and plasma cells, with central necrosis (Fig. 3). In the central necrotic area there is neutrophil polymorph infiltration, nuclear debris and dead amastigotes. In more chronic stages plasma cells disappear and epithelioid cells palisade around necrotic areas, invade them, and are frequently accompanied by Langhans type giant-cells.

Seven cases (11.6%) showed distinct epithelioid granulomas with numerous Langhans type giant cells and plasmacells. These cases were classified in the "reactive tuberculoid group" (Fig. 4) or "type-D groups".

T A B L E 1

Studied cases of cutaneous lesions: histological classification, average P.I. and presence of plasmacells containing Russel bodies

Type of histological response according to Ridley	No. of biopsies	Average PI	No. of cases with plasmacells containing Russel bodies
B	36 (60%)	0.83	12 (20%)
C	14 (23,3%)	1.06	4 (28.5%)
D	7 (11,6%)	0.28	2 (28.6%)
UNCLASSIFIED	3 (5%)	1	— —
Tot.	60 (100%)	0.83	18 (30%)

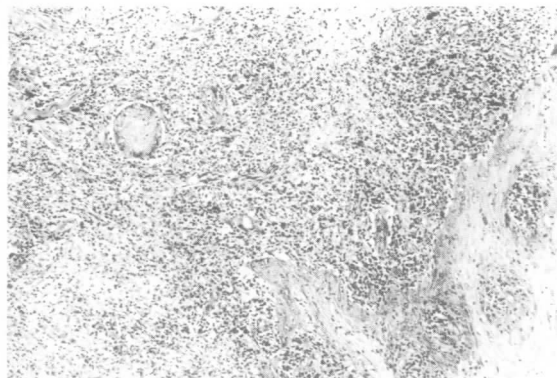


Fig. 1 — Diffuse necrosis: chronic inflammatory infiltrate in the dermis with macrophages, lymphocytes and plasma cells (same case as in Fig. 2). Giemsa stain, x 63.

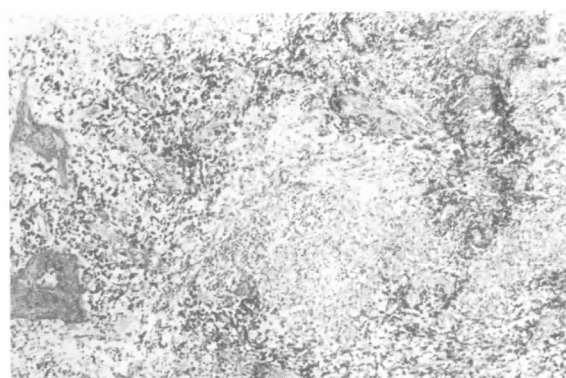


Fig. 3 — Focalized necrosis: necrosis and karyorrhexis in the center of a macrophage granuloma. Giemsa stain, x 63.

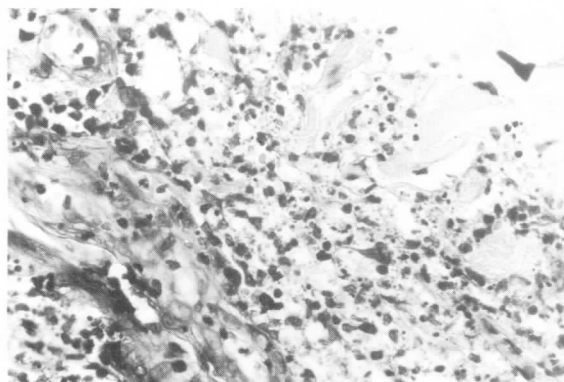


Fig. 2 — Diffuse necrosis: fairly heavily parasitinated macrophages are clearly evident. (same case in Fig. 1). Giemsa stain, x 400.

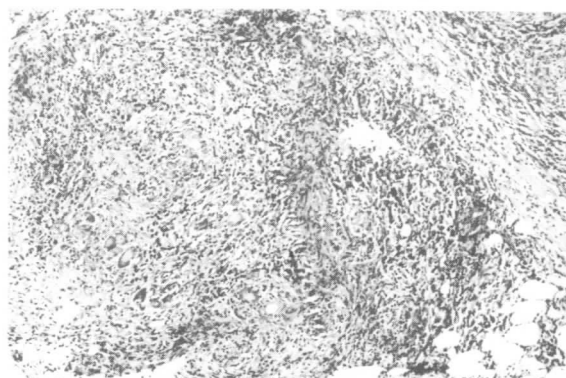


Fig. 4 — Reactive tuberculoid: extensive granuloma with epithelioid and Langhans giant cells. Giemsa stain, x 63.

Because of the scarcity of available tissue 3 biopsies could not be classified into Ridley's groups.

In general, lesion contained very few parasites which were often hardly identifiable. It was frequently necessary to observe slides on oil immersion with a x 100 objective, to

distinguish amastigotes from the nuclear debris of necrotic cells. Using the parasite index (PI) according to RIDLEY & RIDLEY¹⁷ an average value of $PI = 0.83$ was found, with a minimum average value ($= 1.06$) in type C (Tab. 1). Twenty-eight cases (40%) did not present amastigotes ($PI = 0$) and only 8 had a PI equal to 2 or more (Tables 1 and 2).

T A B L E 2

Histogram of PI distribution in the various histological groups

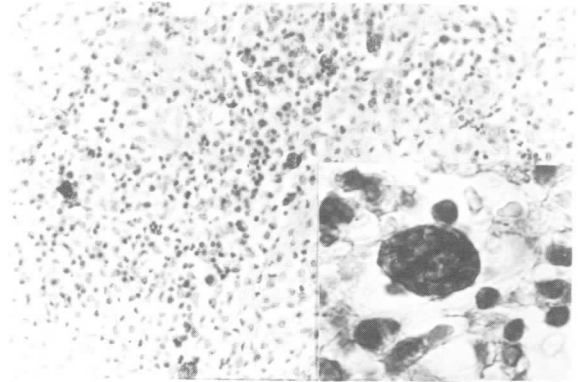
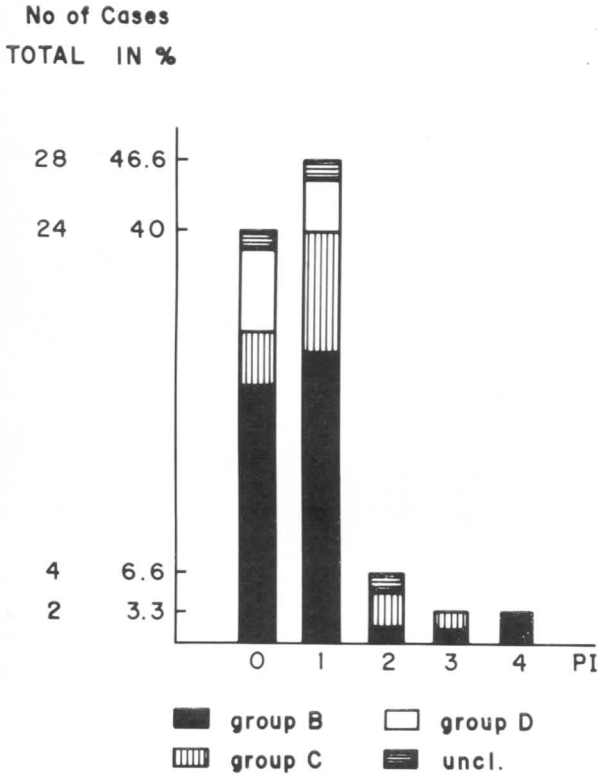


Fig. 5 — Russel bodies: typical morular aspect. PAP immunoperoxidase for detection of IgM, x 250 (insert x 1000).

plasma cells with RB represented 20% of type B lesions, 28.5% of type C and 28.6% of type D. Immunohistochemical investigations to define immunoglobulin heavy chains revealed that in 17 cases plasma cells containing RB were exclusively IgM secreting (Fig. 5) while only in one case were IgG chains found.

DISCUSSION

Nicaraguan cutaneous leishmaniasis has not yet been thoroughly investigated from the pathological point of view^{22,23,24}. The present work seems to be the first histological study performed on local cases, coming from the epidemic zones of the country and especially from the mountain areas of the VI Region. Our histological data appear very similar to those reported by RIDLEY¹³ and RIDLEY & RIDLEY¹⁷ from other countries of Latin America such as Belize and Guyana (Table 3).

T A B L E 3

Comparison of histological classification of leishmaniasis cutaneous lesion in Belize, Guyana and Nicaragua

	B	C	D	UNCL.
	N (%)	N (%)	N (%)	N (%)
BELIZE (Ridley, 17)	5 (38)	8 (62)	excluded	0
GUYANA (Ridley, 17)	18 (62)	11 (38)	excluded	0
NICARAGUA (Our present data)	36 (60)	14 (23,3)	7 (11,6)	3 (5)

In fact the lesion studied were prevalingly of the "diffuse necrosis type" as found in Guyana¹⁷ and had a very low parasite index (PI) as reported for New World cutaneous leishmaniasis¹⁷. Histological aspects and PI values are different from those reported for cuta-

neous leishmaniasis due to *Leishmania tropica*².

The remarkable similarity of the data (Tab. 3) furthermore confirms the utility of Ridley's classification from a diagnostic point of view

Unfortunately we could not carry out a follow-up on the patients concerned because the mountain regions of Nicaragua are involved in the war and therefore we could not look for any correlation between stage of disease, individual immunological reactivity, response to therapy and histological aspects of the lesions. However, there may well be a connection between the type of histological reaction and the particular species of *Leishmania* involved. It is naturally impossible to classify the species and subspecies from an histological point of view but a study of histological patterns relating particular species involved in each case might be interesting.

As already mentioned in previous studies^{3,11} histological lesions of cutaneous leishmaniasis frequently present plasma cells containing globular, hyaline, PAS positive inclusions (Russel bodies). These were found in 18 of the cases studied (30%). In 17 cases, Russel bodies showed IgM-immunoreactivity and in 1 case showed IgG-immunoreactivity. This datum corresponds to previous report by MORIEARTY et al.¹¹ on Cutaneous Leishmaniasis in Brazil. These Authors, however, did not report the histological classification of the lesions under examination. We tried to find a possible correlation between plasma cells containing Russel Bodies and a specific type of histological reaction. This correlation however does not seem to be detectable since the percentage of biopsies showing Russel Bodies is not significantly different from histological group to histological group. Moreover, the plasma cells containing Russel bodies are randomly scattered among the inflammatory infiltrate, without any specific relationship to areas of necrosis or granuloma formations.

At present it seems impossible to give an explanation of the real function of these intracellular inclusions of immunoglobulins: their presence in different histological groups with different tissue reactions, suggests that it is an unspecific mechanism of impaired IgG production and secretion. However, we think that the presence of Russel Bodies^{3,11} may be an adjunctive criterion to RIDLEY's classification¹⁷. Analogously Russel Bodies are a significant diagnostic mean⁸ in other lesions such as those due to *Klebsiella rhinoscleromatis*.

RESUMO

Aspectos histológicos e imunohistoquímicos da leishmaniose cutânea na Nicarágua.

Foram estudadas 60 biopsias cutâneas de 58 pacientes nicaraguenses com leishmaniose tegumentar e ainda não em tratamento terapêutico.

Quase todas as biopsias foram classificadas nos grupos histopatológicos de Ridley: 36 (60%) foram incluídas no grupo B ("diffuse necrosis"), 14 (23%) no grupo C ("focal necrosis"), 7 (11.6%) no grupo D ("reactive tuberculoid"). Somente 3 biopsias ficaram sem classificação.

Não se achou nenhum caso que se pudesse classificar nos grupos A e E.

Em 18 casos, usando método imunohistoquímico, foram observados corpúsculos de Russel. Destes 18 casos 17 eram IgM positivos e só 1 IgG positivo.

Não se descobriu correlação entre os grupos histopatológicos e a presença de corpúsculos de Russel.

Todavia se imagina que os corpúsculos de Russel possam ter um significado diagnóstico (como um critério adjunto).

Pode-se supor também uma correlação entre as numerosas alterações morfológicas e as diferentes espécies de leishmanias.

ACKNOWLEDGEMENTS

We wish to thank Prof. D. S. Ridley, Bland Sutton Institute of Pathology, Middlesex Hospital Medical School, London, for his useful comments and suggestions.

REFERENCES

1. ALLEN, A. C. — The skin. A clinicopathologic treatise. St. Louis, C.V. Mosby Company, 1954. p. 496-501.
2. AZADEH, B.; SAMAD, A. & ARDEHALI, S. — Histological spectrum of cutaneous leishmaniasis due to *leishmania tropica*. *Trans. roy. Soc. trop. Med. Hyg.*, 79: 631-666, 1985.
3. BARBARESCHI, M.; MARISCOTTI, C.; MISSONI, E. & MORELLI, R. — Russel bodies in New World cutaneous leishmaniasis. *Pathologica*, 77: 87-90, 1985.

4. HAGHIGHI, P. & REZAI, H. R. — Leishmaniasis: a review of selected topics. *Path. Ann.*, 12: 63-89, 1977.
5. JANSSEN, P.; VAN BOGAERT, L. & HAYMAKER, W. — Pathology of the peripheral nervous system in African trypanosomiasis. *J. Neuropath. Neurol.*, 15: 269-287, 1956.
6. JONES, T. C. — Interactions between murine macrophages and obligate intracellular protozoa. *Amer. J. Path.*, 102: 127-132, 1981.
7. LAINSON, R. — The American leishmaniasis: some observations on their ecology and epidemiology. *Trans. roy. Soc. trop. Med. Hyg.*, 77: 569-596, 1983.
8. LEVER, W. F. — Histopathology of the skin. Philadelphia, Lippincott, 1977.
9. MAGALHÃES, A. V.; CHIARINI, L. H. & RAICK, A. N. — Histopatologia da leishmaniose tegumentar. *Rev. Inst. Med. trop. S. Paulo*, 24: 268-276, 1982.
10. MISSONI, E. & MORELLI, R. — Survey of 59 cases of American cutaneous leishmaniasis in Nicaragua. *J. trop. Med. Hyg.*, 87: 159-165, 1984.
11. MORIEARTY, P. L.; GRIMALDI, G.; GALVÃO-CASTRO, B.; OLIVEIRA NETO, M. P. & MARZOCHI, M. C. A. — Intralesional plasma cells and serological responses in human cutaneous leishmaniasis. *Clin. exp. Immunol.*, 47: 59-64, 1982.
12. FLORDE, J. J. — Leishmaniasis. In: Harrison's principles of internal medicine. 10th ed. New York, Mc Graw Hill, 1983. p. 873-876.
13. RIDLEY, D. S. — A histological classification of cutaneous leishmaniasis and its geographical expression. *Trans. roy. Soc. trop. Med. Hyg.*, 74: 515-521, 1980.
14. RIDLEY, D. S. — Histopathogenic mechanisms in leishmaniasis. *Pathologica*, 75: 471-479, 1983.
15. RIDLEY, D. S. — The pathogenesis of cutaneous leishmaniasis. *Trans. roy. Soc. trop. Med. Hyg.*, 73: 150-160, 1980.
16. RIDLEY, D. S.; MARSDEN, P. D.; CUBA, C. C. & BARRETTO, A. C. — A histological classification of mucocutaneous leishmaniasis in Brazil and its clinical evaluation. *Trans. roy. Soc. trop. Med. Hyg.*, 74: 508-514, 1980.
17. RIDLEY, D. S. & RIDLEY, M. Y. — The evolution of the lesion in cutaneous leishmaniasis. *J. Path.*, 141: 83-96, 1983.
18. RHODE, R. — Mikroskopische und kulturelle Diagnostik der kutanen Leishmaniose. *Der Hautarzt*, 31: 560-561, 1980.
19. SEHGAL, V. N.; SINGH, K. & GHORPADE, A. — Cutaneous leishmaniasis. A few salient revelations. *Dermatologica*, 166: 111-112, 1983.
20. SELLS, P. G. & BURTON, M. — Identification of *Leishmania* amastigotes and their antigens in formalin fixed tissue by immunoperoxidase staining. *Trans. roy. Soc. trop. Med. Hyg.*, 75: 461-468, 1981.
21. STERNBERGER, L. A.; HARDY, P. H.; CUCULIS, J. J. & MEYER, H. G. — The unlabeled antibody enzyme method of immunohistochemistry. Preparation and properties of soluble antigen-antibody complex (horseradish peroxidase-antihorseradish peroxidase) and its use in identification of spirochetes. *J. Histochem. Cytochem.*, 18: 315-333, 1970.
22. UNDP/WORLD BANK/WHO — Special programme for research and training in Tropical Diseases. *TDR/PR-6/83.7-LEISH*, 1983.
23. URCUYO, F. G. & ZAIAS, N. — Oral ketoconazole in the treatment of leishmaniasis. *Int. J. Derm.*, 21: 414-416, 1982.
24. WHO — The Leishmaniasis. Report of a WHO Expert Committee. *Wld. Hlth. Org. techn. Rep. Ser.*, (701): 43, 1984.
25. WINSLOW, D. J. — Histopathologic diagnosis of protozoal diseases. *Path. Ann.*, 3: 29-54, 1968.

Recebido para publicação em 23/10/86.